

CASE SERIES

Subarachnoid Block as a Sole Anesthesia for Emergency Surgical Procedures in Two High-risk Former Preterm Infants

Anju Gupta^{1*}, Nishkarsh Gupta²¹VMMC and Safdarjung Hospital, New Delhi, India, ²DRBRAIRCH, AIIMS, New Delhi, India**How to cite:** Gupta A, Gupta N. Subarachnoid block as a sole anesthesia for emergency surgical procedures in two high-risk former preterm infants J Neonatal Surg. 2019; 8:2.

This is an open-access article distributed under the terms of the Creative Commons Attribution License, which permits unrestricted use, distribution, and reproduction in any medium, provided the original work is properly cited.

ABSTRACT

Several reports have described spinal anesthesia as a preferred technique of anaesthesia for preterm infants undergoing inguinal herniorrhaphy. However, it is not used routinely probably due to lack of awareness and fear of adverse events. We are reporting the successful use of spinal anaesthesia for two high risk preterm infants posted for emergency procedures.

Key words: Preterm; Spinal anaesthesia; Subarachnoid block

INTRODUCTION

After enjoying initial success and enthusiasm in the pediatric anesthesia practice, subarachnoid block faded in popularity in the middle of the 19th century due to various reasons [1]. It was later reintroduced by Abajian et al. for anesthetizing preterm infants as a safer alternative to general anesthesia (GA) to reduce the post-operative complications such as apnea, bradycardia, and desaturation, which are prevalent in this population [2]. Various reports have supported the use of awake spinal anesthesia over GA for preterm infants undergoing inguinal herniorrhaphy [3,4]. However, there is still a lot of hesitation in the routine use of this technique probably due to lack of awareness, lack of specialized pediatric spinal needles, or fear of adverse consequences. In addition, limited duration of surgical anesthesia in this population, difficult positioning during spinal anesthesia, and unwanted upper limb movement, leading to distraction during surgery, are the limitations related to the technique [2]. The use of spinal anesthesia may lead to some complications such as total spinal anesthesia, transient neurological symptoms, and meningitis which, though exceedingly rare in this group of patients, may deter the anesthesiologist from its routine use [1,3,4]. We are reporting the successful use of spinal anesthesia

for two high-risk preterm infants who were posted for emergency surgical procedures.

CASE REPORT

Case 1

A 2-month-old, 2.46 kg, male baby presented with obstructed hernia. He was having upper respiratory tract infection for the past 3–4 days. A diagnosis of bilateral obstructed inguinal hernia was made, and the child was posted for bilateral inguinal hernia repair. The baby was born preterm at 31 weeks of gestation by cesarean delivery with a birth weight of 1 kg. He was kept in neonatal intensive care unit for 1 week after birth in an incubator. There was no history of mechanical ventilation, cyanosis, or apneic episodes since birth. Fasting status was adequate. Systemic examination and laboratory workup did not reveal any abnormality. His baseline hemoglobin was 15 g/dl. High-risk informed consent was obtained from the parents who consented for spinal anesthesia after detailed discussion of various techniques. In the operating room (OR), standard monitoring including electrocardiography (ECG), non-invasive blood pressure, and pulse oximetry (SpO₂) was attached. The baby was positioned in the left lateral position while maintaining neck extension (Figure 1). After ensuring asepsis,

Correspondence*: Anju Gupta, VMMC and Safdarjung Hospital, New Delhi, India.

E-mail: dranjugupta2009@rediffmail.com

Submitted: 17-12-2018

Conflict of interest: None

© 2018, Gupta and Gupta

Accepted: 21-12-2018

Source of Support: Nil

spinal puncture was attempted in the L4-L5 interspace with 25 G, 30 mm Quincke spinal needle (B Braun®). The first attempt resulted in bloody tap, but on the second attempt, clear CSF was aspirated and 0.5% hyperbaric, bupivacaine 0.5 ml (1 mg/kg) was injected using a tuberculin syringe. Immediate onset motor block was observed in the lower extremity. A paracetamol suppository (60 mg) was inserted before the start of surgery (taking care not to elevate the hips while doing so). Sensory level was checked by skin pinch, and at 5 min, the sensory level was T4 and motor block was modified Bromage score of 3. Oxygen was provided by oxygen hood during surgery. Intraoperative vital parameters remained stable with no episodes of hypotension, bradycardia, or desaturation. One dose of propofol 2 mg was administered to calm the baby during the second attempt to spinal puncture following which no further boluses were required. The surgery lasted 55 min, and at the end of surgery, toe movement was present and sensory level was T12/L1. Complete sensory regression occurred in next 15 min. The child was kept in high dependency unit for 24 h for monitoring and did not develop any episodes of apnea.

Case 2

A 3-week-old, 1.8 kg, male baby presented with complete urinary obstruction and was posted for suprapubic cystostomy. He was born preterm at 35 weeks of gestation by a normal vaginal delivery and had a birth weight of 1.5 kg. The baby had cried immediately at birth and there was no history suggestive of birth asphyxia or respiratory distress after birth. He had been accepting normal feeds. His investigations were unremarkable other than mildly deranged kidney function tests and mild anemia (hemoglobin value of 11.5 g/dl). There was a history of periodic breathing with intermittent apnea and desaturation to 87–88% (without any accompanying bradycardia). The apnea used to resolve spontaneously (within 5 s) without any need for intervention. His postconceptional age at the time of surgery was only 38 weeks, and therefore, spinal anesthesia was considered as the anesthesia modality of choice. After informed high-risk consent, the baby was taken on OT table and routine monitoring was attached. A 24 G intravenous line was secured and i.v. fluid (Ringer's lactate) was started. The baby was positioned in sitting position ensuring head extension and 0.5 ml 1% lignocaine was injected to anesthetize the spinal puncture site over the L5-S1 interspace (Figure 2). After aseptic precautions, lumbar puncture was done using a 25 G, 30 mm Quincke bevel spinal needle (B Braun®). A clear flow of CSF was obtained in a single prick and 0.3 ml (0.8 mg/kg) of hyperbaric, 0.5% bupivacaine was injected using a tuberculin syringe. Thereafter, the baby was positioned supine, oxygen was given by facemask, and the baby was allowed to suck on a sterile ribbon gauze dipped in 10% dextrose. A loss of movement in the lower limbs and loss of sensation to skin pinch was observed at T10 sensory level immediately. Surgery lasted for 35 min and was uneventful. The maximum sensory level was approximately T8 and the

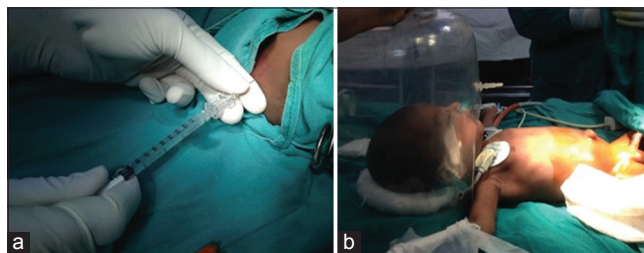


Figure 1: (a) Subarachnoid block in lateral position in the first case, (b) intraoperative positioning

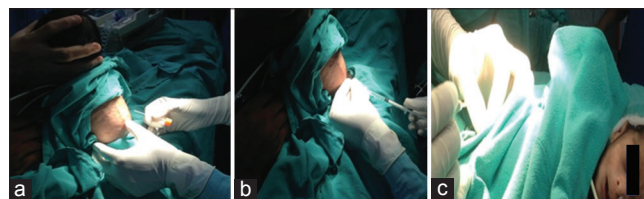


Figure 2: (a) Sitting position for subarachnoid block while maintaining neck extension, (b) local anesthetic injection using tuberculin syringe, (c) the infant during surgery

block regressed at 45 min. After block regression, the baby was allowed to be breastfed. The baby was transferred to HDU postoperatively for overnight monitoring (ECG, SpO₂, and respiratory rate) and oxygen supplementation. His baseline pattern of periodic breathing continued postoperatively, but there were no episodes of desaturation or bradycardia.

DISCUSSION

Anesthetic management of preterm infants is considered challenging due to increased prevalence of multiple comorbidities and their increased tendency for apnea and bradycardia [2–4]. General anesthesia (GA) has been shown to be associated with an increased incidence of post-operative adverse events in this population [3,4]. The incidence of post-operative apnea is inversely proportional to postconceptional age (PCA). This incidence of apnea is maximum till 48 weeks PCA (45%), but elevated risk is believed to persist till 60 weeks PCA [1]. In addition, other important risk factors are a history of pre-operative apneic episodes, bronchopulmonary dysplasia, and anemia [1,4]. However, post-operative apnea can occur without any preceding history of apnea [5]. Hence, elective surgical procedures are preferably delayed beyond this period, and sole regional anesthesia is advocated for these former PT infants within this window to decrease the incidence of post-operative apnea, bradycardia, and desaturation [4,6]. Our patients had 39 and 38 weeks PCA and posted for lower abdominal procedures, and therefore, we planned spinal anesthesia.

Young infants have a narrow thecal sac (6–8 mm) and low CSF pressure. Hence, performing the subarachnoid block requires greater precision and failure rates

are higher [1,5]. Both sitting and lateral positions (with slight head extension to avoid airway obstruction) have been described to be effective [1,3,5]. Sitting and lateral position (with head-up tilt) have been suggested to improve success rates by increasing hydrostatic pressure of CSF [1]. The spinal puncture in the infants of our series was performed in both positions and resulted in successful block. The recommended size of the spinal needle in these patients is 25–30 mm [1]. EMLA cream is preferred for local anesthesia of the lumbar puncture site, but it is not licensed for use in preterm infants >37 weeks [1]. CSF volume is more in infants, and hence, the requirement of drug for subarachnoid block is more and the duration of block is shorter in this population. The recommended dose of bupivacaine for SAB in preterm infants ranges from 0.6 to 1 mg/kg [7]. Shenkman et al. demonstrated 90% satisfactory SAB in preterm infants using 1 mg/kg bupivacaine as compared to 79% in a study by Frumiento et al. who had administered 0.5 mg/kg dose for SAB [6,8]. The use of higher dose had eliminated the need for sedative supplementation in their study [8].

Kurth et al. studied 47 preterm infants undergoing surgeries under GA before 60 postconceptional weeks and found that 18 of the patients had prolonged (>15 s) apnea [9]. They recommended that preterm infants younger than 60 weeks PCA should be monitored for at least 12 h postoperatively using pulse oximetry, respiratory rate, and ECG. Use of these standardized postoperative monitoring is of utmost importance to prevent life-threatening events from occurring as concluded in a recent multicentric trial by Davidson et al. [5] Both of our patients were kept under full monitoring (ECG, pulse oximetry, and respiratory rate) along with overnight oxygen supplementation by oxygen hood. The baby with pre-operative history of periodic breathing continued to have the similar breathing pattern in postoperatively also. These brief periods of apnea resolved spontaneously with no associated bradycardia or need for any intervention other than occasional tactile stimulation by the caregivers.

Previous large series on the use of spinal anesthesia in preterm babies have reported high success rates, low incidence of post-operative pulmonary complications, reduced duration of post-operative fasting, and increased OR turnover rates [6,8]. In both of our cases, there was no post-operative cardiopulmonary complication and one of the babies could be breastfed in less than an hour following surgery. Feeding was delayed due to surgical reason in the other baby.

However, there are certain limitations to the use of spinal anesthesia for preterm infants. First, the failure rate is significant, i.e., 19% in a recent large study [5]. Second, the duration of block is limited and is even shorter for younger infants (60–75 min) [1,7]. Hence, it is not suitable for longer duration procedures and

there is inadequate post-operative analgesia. In both the patients, the effect weaned off quickly (45 min and 70 min). A paracetamol suppository was inserted in the beginning of the case to provide postsurgical pain relief. Hence, an experienced surgeon should perform the surgery to reduce the surgical duration. In addition, sedation may be required to avoid patient movement during the block procedure or during surgery. In one of our patients, a small propofol bolus (2 mg) was administered at the time of lumbar puncture to counter the patient movement. Following this, the baby remained comfortable probably due to the sedation consequent to the deafferentation following the sensory block [10]. In former preterm infants, sedation may increase the incidence of apnea. However, recent evidence suggests that incidence of apnea after RA with sedation is similar to that of RA alone and is better than GA [3].

To conclude, spinal anaesthesia is a safe and effective anaesthetic modality for preterm infants for short lower abdominal surgeries provided vigilant intra and postoperative monitoring is maintained.

REFERENCES

1. Gupta A, Saha U. Spinal anesthesia in children: A review. *J Anaesthesiol Clin Pharmacol*. 2014;30:10-8.
2. Abajian JC, Mellish RW, Browne AF, Perkins FM, Lambert DH, Mazuzan JE Jr, et al. Spinal anesthesia for surgery in the high-risk infant. *Anesth Analg*. 1984;63:359-62.
3. Williams RK, Adams DC, Aladjem EV, Kreutz JM, Sartorelli KH, Vane DW, et al. The safety and efficacy of spinal anesthesia for surgery in infants: The Vermont infant spinal registry. *Anesth Analg*. 2006;102:67-71.
4. Craven PD, Badawi N, Henderson-Smart DJ, O'Brien M. Regional (spinal, epidural, caudal) versus general anaesthesia in preterm infants undergoing inguinal herniorrhaphy in early infancy. *Cochrane Database Syst Rev*. 2003;(3):CD003669.
5. Davidson AJ, Morton NS, Arnup SJ, de Graaff JC, Disma N, Withington DE, et al. Apnea after awake regional and general anesthesia in infants: The general anesthesia compared to spinal anesthesia study – comparing apnea and neurodevelopmental outcomes, a randomized controlled trial. *Anesthesiology*. 2015;123:38-54.
6. Frumiento C, Abajian JC, Vane DW. Spinal anesthesia for preterm infants undergoing inguinal hernia repair. *Arch Surg*. 2000;135:445-51.
7. Libby A. Spinal anesthesia in preterm infant undergoing herniorrhaphy. *AANA J*. 2009;77:199-206.
8. Shenkman Z, Erez I, Freud E, Arnon S. Risk factors for spinal anesthesia in preterm infants undergoing inguinal hernia repair. *J Pediatr (Rio J)*. 2012;88:222-6.
9. Kurth CD, Spitzer AR, Broennle AM, Downes JJ. Post-operative apnea in preterm infants. *Anesthesiology*. 1987;66:483-8.
10. Hermanns H, Stevens MF, Werdehausen R, Braun S, Lipfert P, Jetzek-Zader M, et al. Sedation during spinal anaesthesia in infants. *Br J Anaesth*. 2006;97:380-4.