

## Case Report

© 2020, Raghunath et al

Submitted: 02-07-2020

Accepted: 15-07-2020

License: This work is licensed under a [Creative Commons Attribution 4.0 International License](https://creativecommons.org/licenses/by/4.0/).

DOI: <https://doi.org/10.47338/jns.v9.535>

## Ileo-colonic tubular duplication with distal sigmoid colon stenosis in a neonate: A case report

Raghunath BV,<sup>1\*</sup> Veerabhadra R,<sup>1</sup> Varsha JS,<sup>2</sup> Janaki SR,<sup>3</sup> Prasad NA,<sup>3</sup> Naresh Kumar Y,<sup>3</sup>

1 Consultant Pediatric Surgeons, Rangadore Memorial Hospital, Bengaluru

2 Fellow in Neonatology, Rangadore Memorial Hospital, Bengaluru

3 Consultant Neonatologist, Rangadore Memorial Hospital, Bengaluru

**Correspondence\***: Dr. Raghunath BV, Consultant Pediatric Surgeon, Rangadore Memorial Hospital, Shankarapuram, Basavanagudi, Bengaluru, 560004. E-mail: [bvraghunath9@gmail.com](mailto:bvraghunath9@gmail.com)

### KEYWORDS

Neonate  
Tubular  
Ileo-colon  
Duplication cyst  
Intestinal obstruction

### ABSTRACT

**Background:** Though the duplication cysts presenting with intestinal obstruction are not uncommon in neonates, tubular duplications may pose a significant diagnostic and management challenge.

**Case Presentation:** We present the successful management of a neonate presenting with intestinal obstruction. The diagnosis of ileocolonic tubular duplication cyst was made intra-operatively. The cyst was managed with a novel technique.

**Conclusion:** Tubular duplications of the alimentary tract rarely encounter in neonates. The surgeons should improvise the surgical technique to manage such anomalies.

### INTRODUCTION

Duplication cysts are rare congenital anomalies of the gastrointestinal tract (GIT) with an incidence of 1 in 4000-5000 live births. [1] Morphologically, they may be either cystic or tubular. Many of the cystic masses can be detected antenatally with ultrasound. However, a few lesions pose a significant challenge in diagnosis and present as an intra-operative surprise. A thorough literature search revealed many authors describing their experience in the management of such lesions. However, to the best of our knowledge, this is the first case report of an ileocolonic tubular duplication cyst associated with distal sigmoid colon stenosis.

### CASE REPORT

A 3-day-old male baby (term, birth weight: 3.1kg) born to a primigravida mother with no significant antenatal history presented with a history of failure to pass meconium and progressive abdominal distension since birth. Examination revealed normal vital parameters with mild abdominal distension and normal anal opening. X-ray abdomen revealed dilated bowel loops with a paucity of gas in the pelvis. Rectal wash was attempted with a provisional diagnosis of Hirschsprung disease (HD) but was ineffective. Contrast enema outlined a narrow rectum but could not traverse beyond the recto-sigmoid region.

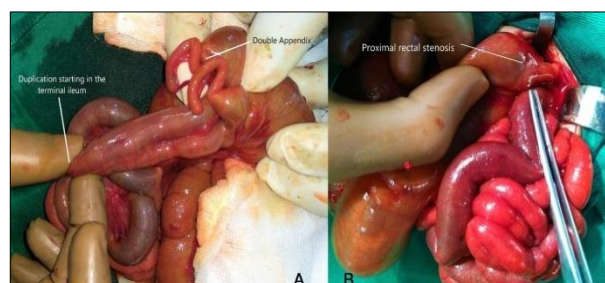


Figure 1: Showing tubular duplication of terminal ileum and colon with double vermiform appendix (A) and distal sigmoid stenosis (B).

At surgery, a long tubular Ileo-colonic duplication cyst extending from 15cm proximal to the ileocecal junction (ICJ) to the distal sigmoid colon was encountered, along with double vermiform appendix (Fig. 1A, 1B).

Distal sigmoid colon stenosis was noted at the recto-sigmoid junction- where the duplication was just ended. However, the anal canal and distal rectum were patent. The tubular duplication was communicating with the ileum. An end sigmoid colostomy (containing both duplicating segments) was formed with excision of the stenotic segment. The distal rectal stump was closed as Hartmann's pouch. Seromuscular biopsies were taken to exclude HD. Biopsy revealed good ganglion cells without any ectopic tissue. The postoperative course remained uneventful. The baby was discharged on the 8th postoperative day.

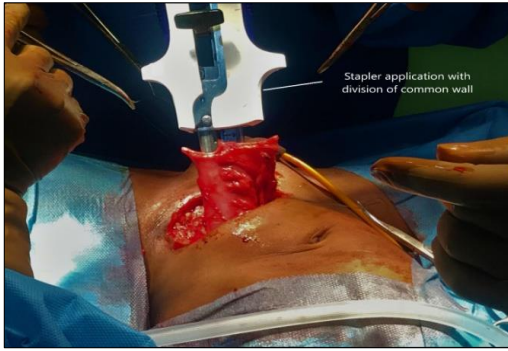


Figure 2: Showing unification of two normal and duplicated colons with the help of GIA linear cutter.

At 1 year of age, the baby was booked for the definitive procedure. Sigmoid stoma was mobilized. The common wall between the duplicating segments was divided using a 75mm linear cutting stapler (Ethicon) (Fig.2). Distal Hartmann's stump was mobilized and end to end anastomosis was completed. Both appendices were removed. The postoperative course was uneventful, and the patient was discharged on the 5th postoperative day. At a follow-up of 1.5 years, the toddler is doing well.

## DISCUSSION

Duplication cysts are rare congenital anomalies which mainly present within the first 2 years of life.[2] The ileum is the common site of occurrence.[3,4] Clinical presentation depends on the age, location, size, presence, or absence of ectopic mucosa and complications.[5] Common symptoms include pain abdomen, vomiting, mass, bleeding per rectum, and rarely intestinal obstruction. In the index case, the neonate presented with neonatal intestinal obstruction.

Morphologically, cystic duplications are much common (75%) and are usually seen on the mesenteric side whereas tubular duplications usually run parallel to the adjacent bowel with or without internal communication. [5,6] Preoperative diagnosis of cystic duplications can be made on ultrasound and imaging; however, tubular duplications are difficult to diagnose on imaging, especially on ultrasonography. In the

index case, we thought of rectal stenosis based on contrast enema findings, which was confirmed at the surgery in addition to tubular duplication of ileo-colon.

Surgical excision depends on the location, extent, and type of the duplication. Resection of the duplication with end to end anastomosis is commonly performed for cystic variety though other techniques such as segmental resection, fenestrations, and mucosal stripping are also performed for certain varieties of the duplication.[7] In our case, the duplication had extensively involved the terminal ileum and entire colon, therefore, complete resection of the duplication was not a good option fearing short bowel syndrome. As the tubular duplication was communicating with the ileum, we preferred a stoma involving both the normal and the duplicated colons as a first stage procedure in addition to resecting recto-sigmoid stenosis. Subsequently, during the definitive procedure, we divided the common wall using a linear cutting stapler and converted it into a single lumen and anastomosed it to the rectal stump. The other alternative would have been a mucosectomy of the duplicated ileo-colon. The child is on follow up for the past 1.5 years and is asymptomatic. Parents have been counseled regarding the risk of bleeding per rectum as we have not ruled out the possibility of an ectopic gastric mucosa in the duplicated bowel.

In conclusion, tubular duplication involving terminal ileum and entire colon with associated distal sigmoid colonic stenosis is an exceedingly rare entity which demands an improvised surgical decision making as we had in the index case.

**Acknowledgments:** Nil

**Conflict of Interest:** None declared

**Source of Support:** Nil

**Consent to Publication:** Author(s) declared taking informed written consent for the publication of clinical photographs/material (if any used), from the legal guardian of the patient with an understanding that every effort will be made to conceal the identity of the patient, however it cannot be guaranteed.

**Author Contributions:** Author(s) declared to fulfil authorship criteria as devised by ICMJE and approved the final version.

## REFERENCES

- Górecki W, Bogusz B, Zajac A, Soltysiak P. Laparoscopic and laparoscopy assisted resection of enteric duplication cysts in children. *J Laparoendosc Adv Surg Tech.* 2015; 25:838-40.
- Rattan KN, Bansal S, Dhamija A. Gastrointestinal duplication presenting as neonatal intestinal obstruction: An experience of 15 years at tertiary care centre. *J Neonatal Surg.* 2017; 6:5.
- Khan RA, Wahab S, Ghani I. Neonatal intestinal obstruction: When to suspect duplication cyst of bowel as the cause. *J Neonatal Surg.* 2016; 5:52.
- Okur MH, Arslan MS, Arslan S, Aydogdu B, Turkcu G, Goya C, et al. Gastrointestinal tract duplications in children. *Eur Rev Med Pharmacol Sci.* 2014; 18:1507-12.
- Mayer JP, Bertolli M. Alimentary tract duplications in newborns and children: Diagnostic aspects and the role of laparoscopic treatment. *World J Gastroenterol.* 2014; 20:14263-71.
- Nebot CS, Salvador RL, Palacios EC, Aliaga SP, Pradas VI. Enteric duplication cysts in children: varied presentations, varied imaging findings. *Insights into Imaging.* 2018; 9:1097-106.
- Schalamon J, Schlee J, Höllwarth ME. Experience with gastrointestinal duplications in childhood. *Langenbecks Arch Surg.* 2000; 385:402-5.